

Gary Leonard
Paulo Coelho
Ioannis Polyzois
Leo Stassen
Noel Claffey

A study of the bone healing kinetics of plateau versus screw root design titanium dental implants

Authors' Affiliations:

Gary Leonard, Leo Stassen, Department of Oral and Maxillofacial Surgery, Trinity College, School of Dental Science, Dublin, Ireland
Paulo Coelho, New York University 345 24th Street 804a, New York, New York 10010, Department of Biomaterials and Biomimetics
Ioannis Polyzois, Noel Claffey, Department of Restorative Dentistry and Periodontology, Trinity College, School of Dental Science, Dublin, Ireland

Correspondence to:

Prof. Noel Claffey
School of Dental Science, Trinity College
Dublin 2, Ireland
Tel.: +353 1 6127 306
Fax: +353 1 6711 255
e-mail: nclaffey@dental.tcd.ie

Keywords: endosseous implants, implant design, osseointegration

Abstract

Objective: This study was designed to compare the bone healing process around plateau root from (PRF) and screw root from (SRF) titanium dental implants over the immediate 12 week healing period post implant placement.

Material and methods: 32PRF and 32SRF implants were placed in 8 beagle dogs at 12, 8, 5 and 3 weeks prior to euthanasia using a bilaterally balanced distribution. Undecalcified ground sections were prepared from the biopsies taken and histometric measurements of bone implant contact (BIC) and bone area fraction occupancy (BAFO) were made on the middle 5 mm portion of each 8 mm implant root length.

Results: The analysis showed that although measurements of bone to implant contact (BIC) and bone area fraction occupancy (BAFO) tended to be greater for the SRF implants at all four time points, the differences in measurements between implant types did not reach statistical significance ($P = 0.07$, $P = 0.06$). The effect of time on BIC and BAFO was found to be strongly significant for both implant types thus indicating a statistically significant increase in BIC and BAFO overall with time ($P = 0.004$, $P = 0.002$). Furthermore, both PRF and SRF implants behaved similarly over time with measurements of BIC and BAFO progressing in parallel. Histomorphologic analysis of these sections demonstrated the prominent role of woven bone (callus) in the bone healing process around PRF implants.

Conclusion: The results can be interpreted to indicate a comparable development of secondary stability for both PRF and SRF implant designs. However, as these parameters reflect the structural connection between implant and bone and not the functional properties of the bone to implant interface, they cannot be regarded as comprehensive measures of osseointegration. This particularly relevant given the reduced load bearing capacity of woven bone.

In the intervening years since Brånemark et al.'s (1969) seminal publication on the osseointegration of screw root form (SRF) titanium dental implants, these implants have become widely accepted. The bone healing process around SRF endosseous dental implants has been well documented in scientific literature (Adell et al. 1981; Albrektsson et al. 1981; Roberts 1988). A wide variety of different endosseous implant morphologies have been tried over

the years but many have fallen out of use due to an inability to satisfy established success criteria (Albrektsson et al. 1986; Smith & Zarb 1989; Albrektsson & Sennerby 1991; Fiorellini et al. 1998).

The plateau root form (PRF) endosseous dental implant, also referred to as a finned or serrated implant, has been employed in a number of guises since the early 1970s (Driskell et al. 1971; Chess 1990). It is currently available as Bicon[®] dental im-

Date:
Accepted 31 August 2008

To cite this article:
Leonard G, Coelho P, Polyzois I, Stassen L, Claffey N. A study of the bone healing kinetics of plateau versus screw root design titanium dental implants. *Clin. Oral Impl. Res.* 20, 2009; 232–239.
doi: 10.1111/j.1600-0501.2008.01640.x

plant. The PRF dental implant differs from SRF dental implants in having a series of separate circumferential fins spaced along the bone-interfacing portion of the implant. One potential significance of this design is that there is a large space available between the fins of the implant in which a blood clot can form and in which woven (callus-like) bone can develop. It has been suggested that the vascularisation and filling sequence in this space could result in a relatively rapid biomechanical stabilisation of the implant (Lemons 2004).

The premise that the bone healing process around PRF implants differs from that around SRF implants is based on a very small body of literature (Lemons 2000; Coelho & Suzuki 2005). Berglundh et al. (2003) and Buser et al. (2004) have provided histological evidence of prominent woven bone formation and maturation within experimental wound chambers cut into the surface of non-PRF implants. The aim of this study was to perform a histological comparison of the bone healing process around PRF and SRF implants over the initial 12-week healing period post implant placement using an *in vivo* beagle model.

Materials and methods

The devices

The SRF dental implants used in this study were Standard Plus Narrow Neck design implants (Straumann® AG, Basel, Switzerland). The implants were manufactured from commercially pure titanium (CPTi) with sand-blasted and acid-etched root surface (3.3 mm in diameter × 8 mm in length) and a machined collar (1.8 mm) and external octagon attachment (Fig. 1). The vertical distance between root threads was 1 mm and the maximum distance between the central root shaft and tip of the root threads was 0.25 mm. The machined collar flared out to a diameter of 3.5 mm at its upper border. A machined narrow neck cover screw was utilised post implant placement.

The PRF dental implants used in this study were custom manufactured by Bicon® Inc. (Boston, MA, USA). The implants were manufactured from titanium alloy with a grit-blasted and acid-etched root surface (3.3 mm in maximum diameter × 8 mm in length) and a machined

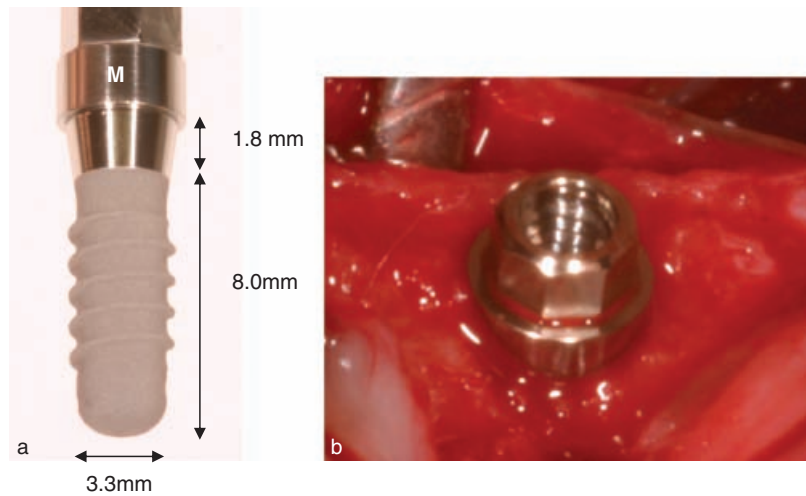


Fig. 1. Standard Plus Narrow Neck dental implant with (a) external octagon connection obscured by mount (M) and (b) with external octagon visible after mount has been removed and before cover screw has been attached.




Fig. 2. Plateau root form dental implant (a) with mount (purple) inserted into external octagon connection and (b) with cover screw C being screwed down over the external octagon connection.

collar (1.8 mm in height × 3.5 mm upper border diameter). The vertical distance between root plateaus was 0.75 mm and the maximum distance between the central root shaft and tip of the root plateaus was 0.75 mm (Fig. 2). The PRF implants also had an external octagon attachment identical to that present on the SRF implant thus facilitating the use of the same cover screw (Straumann® narrow neck cover screw).

Similar root surface topographies (sand-blasted and acid-etched) and supracrestal morphologies (external octagon and a machined collar 1.8 mm in height × 3.5 mm upper border diameter) were deliberately employed for both implant designs in order to minimise non-root morphology variables.

Experimental animals

The mandibular premolar regions of eight young adult male Beagle dogs were used for the study. The protocol followed was in accordance with the animal research policies of the Department of Health in Ireland.

All surgical procedures were performed under general anaesthesia. Food was withheld for 12 h before each procedure. The animals were premedicated 30 min preoperatively with 0.1 mg/kg of acetyl promazine (Acepromazine maleate BP; Novartis® Basel, Switzerland; 2 mg/ml) by subcutaneous injection. Anaesthetic induction was achieved with 0.05 mg/kg of thiopentone sodium (Rhône Mérieux, Dublin, Ireland) intravenously. An endotracheal tube was inserted and anaesthesia was maintained

Table 1. Implant location per animal, time-point, site and implant morphology

Dog no.	Week*	Site	Implant morphology	Dog no.	Week*	Site	Implant morphology
1 and 5	12	RP1	PRF	2 and 6	8	RP1	PRF
1 and 5	12	LP1	SRF	2 and 6	8	LP1	SRF
1 and 5	8	RP2	PRF	2 and 6	5	RP2	PRF
1 and 5	8	LP2	SRF	2 and 6	5	LP2	SRF
1 and 5	5	RP3	SRF	2 and 6	3	RP3	SRF
1 and 5	5	LP3	PRF	2 and 6	3	LP3	PRF
1 and 5	3	RP4	SRF	2 and 6	12	RP4	SRF
1 and 5	3	LP4	PRF	2 and 6	12	LP4	PRF
3 and 7	5	RP1	PRF	4 and 8	3	RP1	PRF
3 and 7	5	LP1	SRF	4 and 8	3	LP1	SRF
3 and 7	3	RP2	PRF	4 and 8	12	RP2	PRF
3 and 7	3	LP2	SRF	4 and 8	12	LP2	SRF
3 and 7	12	RP3	SRF	4 and 8	8	RP3	SRF
3 and 7	12	LP3	PRF	4 and 8	8	LP3	PRF
3 and 7	8	RP4	SRF	4 and 8	5	RP4	SRF
3 and 7	8	LP4	PRF	4 and 8	5	LP4	PRF

PRF, plateau root form; SRF, screw root form.
*Weeks pre-euthanasiation.

with halothane (Halothane[®], Mumbai, India) and oxygen. Local infiltration with 2% Lidocaine and 1/80,000 epinephrine was used for analgesia and to aid in haemostasis (Lignospan special[®] Septodont; Mazamet Cedex, France).

The mandibular premolars (P₁, P₂, P₃, P₄) were removed on both sides. To facilitate the removal, a buccal mucoperiosteal flap was raised. The surgical sites were sutured with absorbable sutures (3/0 Vicryl Rapide; Ethicon[®], Johnson and Johnson[®] Langhorne, Pennsylvania, USA) and the dogs were allowed to recover from the anaesthetic. They were reinstalled in kennels where they were kept for a healing period of 3 months.

The animals were given 1 ml of carprofen (Rimadyl; Pfizer[®], New York City, New York, USA; 50 mg/ml) subcutaneously for analgesia at the time of extractions and once daily for the next 5 days. They were also given 150 mg of oral clindamycin (Antirobe; Pharmacia, New York City, New York, USA; 150 mg capsules) on the day of the procedure and once daily for the following 5 days.

Following the 3-month healing period, eight dental implants were placed in each dog over four separate time-points at 12, 8, 5 and 3 weeks pre-euthanasiation. General anaesthesia was administered as described earlier. The implants were placed using a bilaterally balanced distribution, such that at each time-point a PRF and a SRF implant were placed at the same site but on opposite sides of the mandible (Table 1).

Buccal and lingual soft tissue flaps were raised at the experimental sites. A minimum of 4 mm of vital bone was maintained between implant surfaces and the flap surgery was carried out as conservatively as possible in order not to affect the healing around the previously placed implants. The SRF implant osteotomies were prepared according to the Straumann[®] surgical protocol. The sterile SRF implant was placed manually to engage the full depth of the 9 mm osteotomy. This resulted in the subcrestal positioning of the sand-blasted and acid-etched root surface (8 mm) and a portion (1 mm) of the machined collar. A cover screw was then placed followed by careful flap repositioning using 3.0 absorbable sutures (Vicryl Rapide, Ethicon[®], Johnson and Johnson[®]) (Fig. 3a–h).

The PRF implants were placed according to the Bicon[®] surgical protocol with the exception of depth of placement. Conventional Bicon[®] implants (have a sloping shoulder, internal taper connection and no machined collar) are normally placed 3 mm below the bone crest to allow for bone overgrowth over the top of the implant body. In this instance, a sterile PRF implant was placed manually to engage the full depth of the 9 mm osteotomy. This resulted in the subcrestal positioning of the sand-blasted and acid-etched root surface (8 mm) and a portion (1 mm) of the machined collar. A cover screw was then placed followed by careful flap repositioning using 3.0 absorbable sutures (Vicryl Rapide, Ethicon[®], Johnson and Johnson[®])

(Fig. 4a–f). They were given 1 ml of carprofen (Rimadyl; Pfizer; 50 mg/ml) subcutaneously for analgesia at the time of implant surgery and once daily for the next 5 days. In addition, 3 ml of the antibiotic enrofloxacin (Baytril; Bayer AG, Leverkusen, Germany; 50 mg/ml) was administered subcutaneously at the time of implant surgery followed by 150 mg of oral clindamycin (Antirobe; Pharmacia; 150 mg capsules) once daily for the next 5 days.

The animals were reinstalled in kennels after each procedure and were sacrificed by intravenous injection of 200 mg/kg of pentobarbitone (Rhône Mérieux) after 24 weeks (12 weeks post first implant placement session). Block biopsies were harvested and placed in 10% formalin. The specimens were then rinsed in running tap water, trimmed and dehydrated using a graded series of increasing ethanol concentrations. They were embedded in methylmethacrylate without being decalcified.

Tissue blocks were cut in the buccolingual plane parallel to the long axis of the implant into 1000 µm thick vertical sections using a slow speed diamond precision saw (Isomet[®] 1000; Buehler GmbH, Düsseldorf, Germany). The sections were ground and polished to a final thickness of 80–100 µm using a series of silicon carbide coated paper discs on a variable speed polishing wheel (Metprep 10 DVT; Metprep Ltd, Coventry, UK) and surface stained with a 1% aqueous solution of toluidine blue (Donath & Breuner 1982; Rohrer & Schubert 1992).

The slides were analysed using light microscopy 12.5 × (Olympus IX-51 inverted research microscope; Olympus, Tokyo, Japan). Digital micrographs of each specimen were captured (Olympus DP-70 digital camera, Olympus). The micrographs (*TIF format), were transferred to a personal computer and histomorphometric analysis was performed using analysis software (AnalySIS[®]; Soft Imaging System GmbH, Münster, Germany).

Histomorphometric analyses were carried out for each implant with the measurement of bone-to-implant contact (BIC) and bone area fraction occupancy (BAFO). A rectangular grid 5 mm (5000 µm) in length was superimposed on the middle 5 mm portion of each 8 mm implant body (Figs 5 and 6). Both BIC and BAFO were measured within the confines of this grid, thus

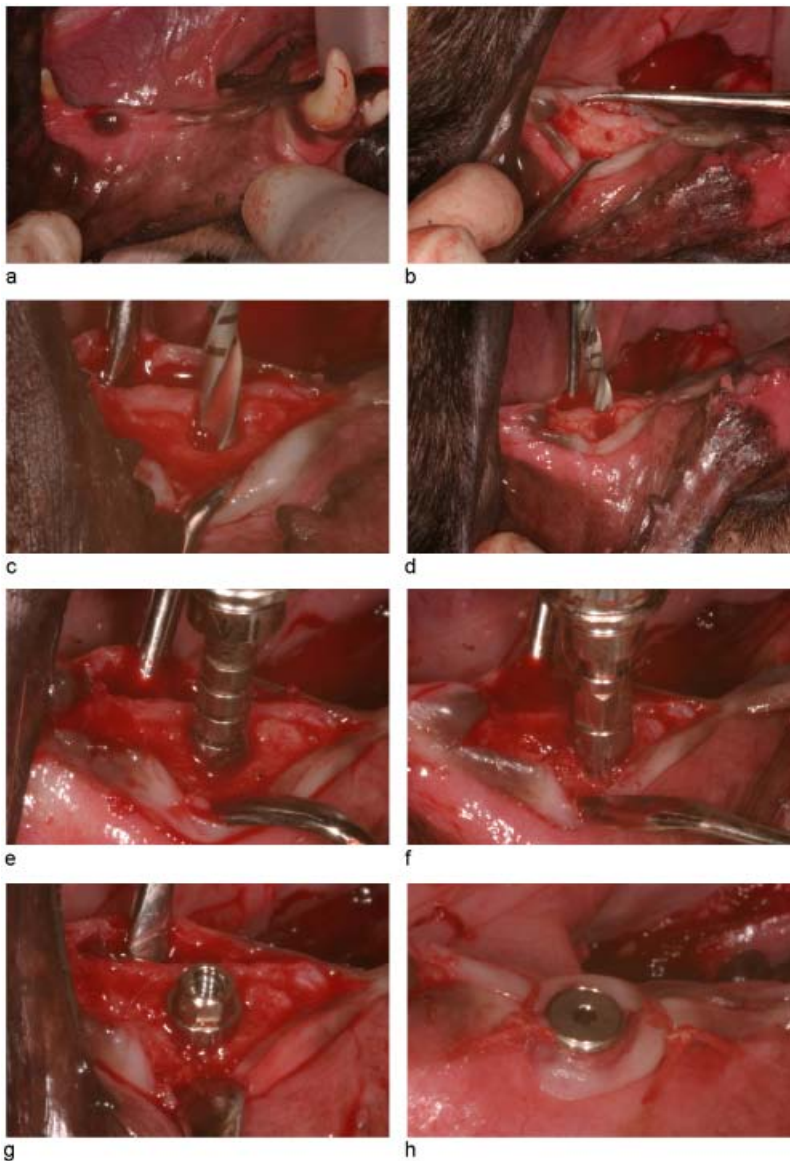


Fig. 3. (a) Edentulous ridge. (b) Pilot hole marked. (c) 2.2 mm twist drill. (d) 2.8 mm twist drill. (e) Manual bone tapping. (f) Manual implant insertion. (g) Screw root form implant *in situ*. (h) Cover screw in position.

excluding measurements in the apical and coronal 1.5 mm of each implant body. The BIC values generated represent the total BIC (mm) within the grid expressed as a percentage of the total implant perimeter (mm) within the grid (Fig. 7). The BAFO values generated represent the area of bone (mm²) within the retentive features of each implant expressed as a percentage of the total area (mm²) between the retentive features of each implant (restricted to the middle three interthread/interplateau areas in each grid) (Fig. 8).

Data analysis

The data was analysed using the statistical software package JMP 5.2 (SAS Institute,

Cary, NC, USA). Repeated measures analysis of variance tests were employed (MANOVA) to investigate (1) the effect of implant type on BIC and BAFO over time, (2) the effect of time on BIC and BAFO and (3) the effect of the interaction of implant type and time on BIC and BAFO.

Results

For the calculation of %BIC and %BAFO, a total of 48 of the 64 implants originally placed were included in the results (22 × PRF, 26 × SRF). Sixteen implants were excluded from the results (10 × PRF, 6 × SRF). From the excluded implants 12

(10 × PRF, 6 × SRF) that were placed in the P1 ridge region were in contact with the root of the adjacent cuspid tooth. This resulted in the fibrous encapsulation of the implants and a failure of osseointegration. The remaining four (4 × PRF) all failed probably due to insufficient primary stability. The failed implants were distributed evenly between the different healing times (five at 12 weeks, four at 8 weeks, three at 5 weeks and four at 3 weeks).

The results for percentage BIC and BAFO for PRF and SRF implants in groups corresponding to the four time-points of implant insertion are presented in Figs 9a–e and 10a–e, respectively. The BIC results recorded for the SRF implants were higher at four time-points, increasing from 70.9% at 3 weeks to 89.6% at 12 weeks. For the PRF implants, they increased from a low of 57.5% at 3 weeks to a high of 84.4% at 12 weeks. The BAFO results recorded for the SRF implants were higher at all four time-points, increasing from 58.2% at 3 weeks to 74.7% at 12 weeks. The results for the PRF implants increased from a low of 43.1% at 3 weeks to high of 63.7% at 12 weeks.

Regarding the effect of time on BIC and BAFO, it was shown to be statistically significant (d.f. = 3, F -ratio = 33.2426, P = 0.004) and (d.f. = 3, F -ratio = 17.1611, P = 0.0024), respectively. This indicates a statistically significant increase in BIC and BAFO overall (for both implant types) with time.

The effect of implant type on BIC and BAFO approached but fell just short of being significant. (d.f. = 1; F -ratio = 4.2865, P = 0.0722) and (d.f. = 1; F -ratio = 4.5230, P = 0.0661), respectively. Non-significant was also the effect of the interaction of implant type and time, which indicates that with regard to BIC and BAFO, both types of implant behaved similarly over-time.

Discussion

The bone healing process around SRF implants has been well documented and a wealth of supporting histological evidence exists as to the role of bone modelling and remodelling at the bone to implant interface (Brånemark et al. 1969; Albrektsson et al. 1981; Roberts 1988; Suzuki et al. 1997; Davies 2005). However, the premise

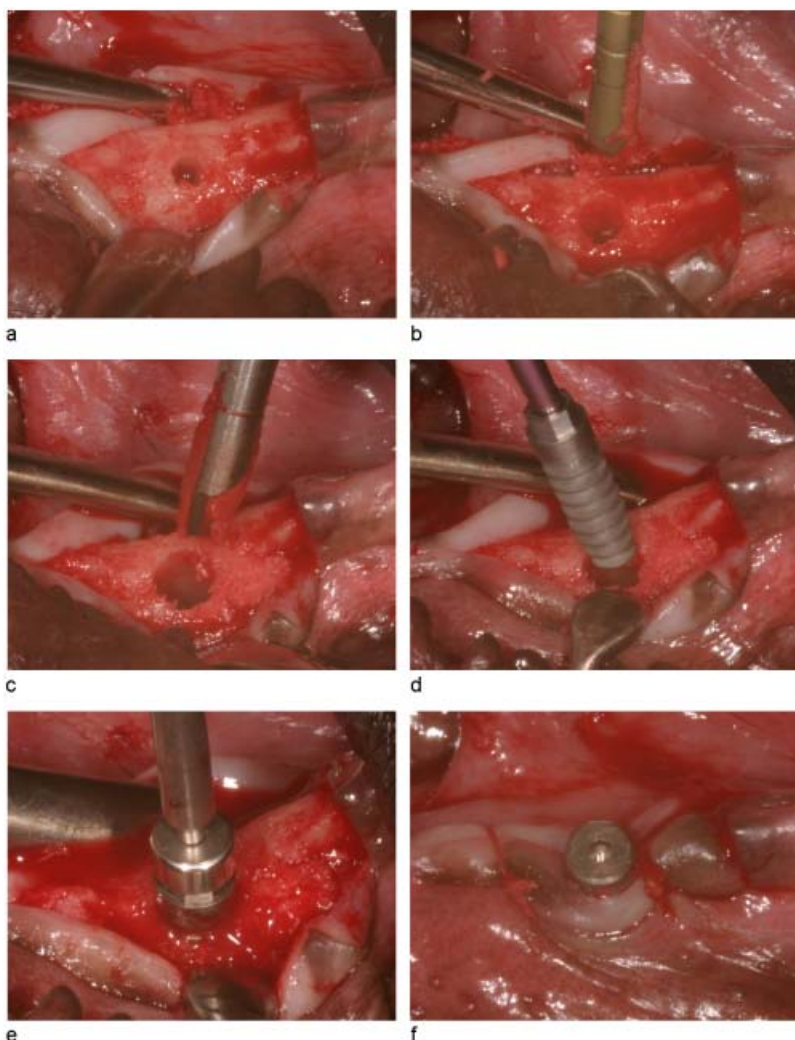


Fig. 4. (a) 2 mm twist drill osteotomy. (b) 2.5 mm latch reamer. (c) 3.3 mm latch reamer. (d) Plateau root form implant placement. (e) Cover screw insertion. (f) Flap closure.



Fig. 7. Photomicrograph of plateau root form inter-plateau space with tracings for bone-to-implant contact as recorded using image analysis software ($\times 12.5$ with zoom).

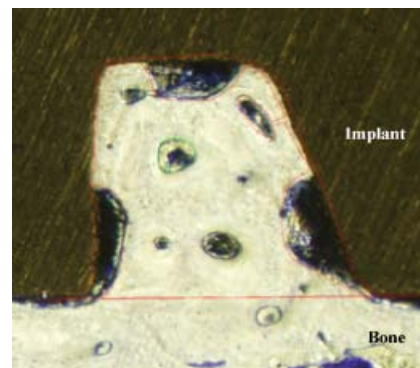


Fig. 8. Photomicrograph of plateau root form inter-plateau space with tracings for measurement of bone area fraction occupancy as recorded using image analysis software ($\times 12.5$ with zoom).




Fig. 5. Photomicrograph of plateau root form implant with 5 mm length grid superimposed over the middle 5 mm of the 8 mm root length ($\times 12.5$). The letter N denotes neurovascular bundle.

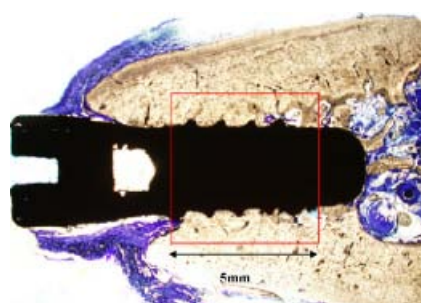


Fig. 6. Photomicrograph of screw root form implant with 5 mm length grid superimposed over the middle 5 mm of the 8 mm root length ($\times 12.5$).

that the bone healing process around PRF implants differs from that around SRF implants is based on a very small body of literature.

Lemons (2002) performed a qualitative histological analysis of PRF and SRF dental

implants explanted from humans for reasons other than a failure of osseointegration. Based on his findings, Lemons (2002) suggested that the bone healing process around PRF implants differs from that around SRF implants, in having a greater

contribution from woven bone formation. However, as all the implants had been in clinical function for more than a year, Lemons (2002) had no histological evidence of woven bone infill in the early bone healing phase (0–3 months). Unlike his work, this study provided definitive histological evidence of the significant role of intramembraneous ossification in the osseointegration of PRF implants in the 0–3 month healing phase. Furthermore, through qualitative histological analysis, it was possible to show that intramembraneous ossification played a more prominent role in the peri-implant bone healing process around the PRF implants than it did for the SRF implants that were placed at the same time-points.

This study was unique in having the expressed aim of comparing the bone healing process in PRF and SRF dental implants. The parameters BIC and BAFO are long established measures of osseointegration in scientific literature (Sennerby

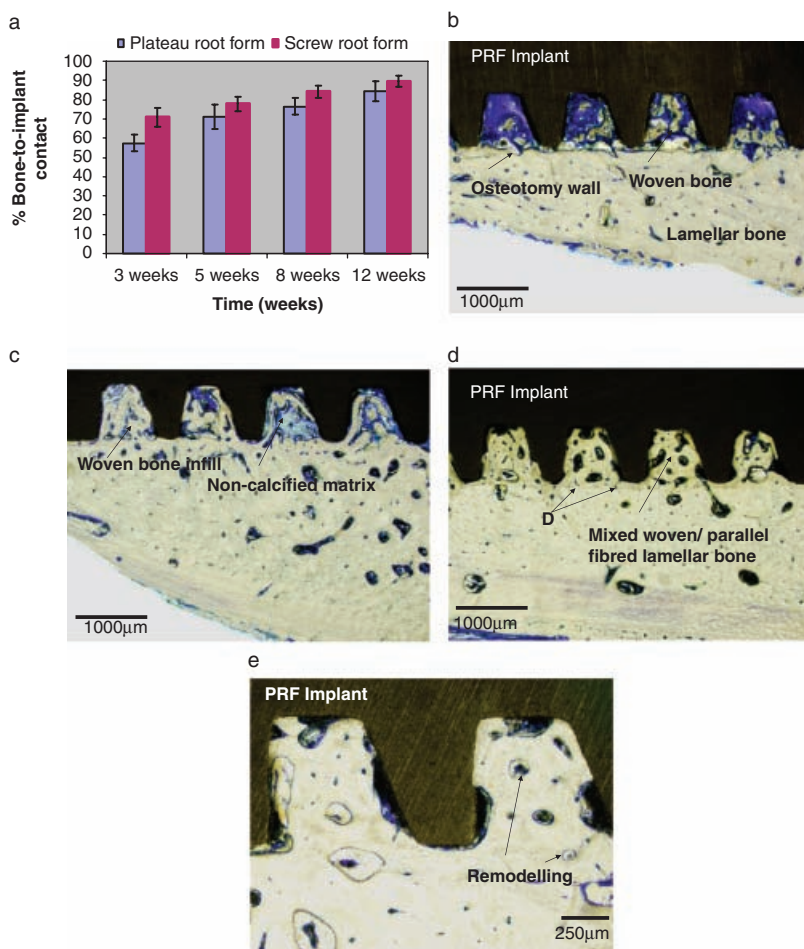


Fig. 9. (a) Graphic representation of mean %BIC (% bone-to-implant contact) and SE (error bars) for each time-point for plateau root form (PRF) and screw root form (SRF) implants. (b) Photomicrograph of ground section of PRF implant 3 weeks after placement ($\times 40$). (c) Photomicrograph of ground section of PRF implant 5 weeks after placement ($\times 40$). (d) Photomicrograph of ground section of PRF implant 8 weeks after placement ($\times 40$). (e) Photomicrograph of ground section of PRF implant 12 weeks after placement ($\times 100$).

2001). It is well recognised that the proportion of BIC depends on a number of factors including implant material, surface characteristics, surgical technique and site, time and implant design (Albrektsson et al. 1993). The study was structured so as to minimise the effect of all but the last of these variables, as the effect of implant design was the focus of our attention. While the PRF and SRF implants were made from titanium alloy and CPTi, respectively, they both had a sand-blasted and acid-etched surface. The authors are unaware of studies that compare similar surface treatments with different implant materials. The existing studies report on isolated variables and do not combine them because it is not possible to separate, for example, the effects of surface treatment from surface chemistry (CPTi or titanium alloy), or the effects that the surface treat-

ment has on the surface chemistry. The lack of such data makes it difficult to draw any real conclusions on the similarities between these two surfaces.

While the surgical techniques differed, neither process was considered to be excessively traumatic. With regard to site and time of implant placement, a bilaterally balanced model of implant placement was employed to ensure that at each time-point, PRF and SRF implants were placed in the same surgical site but on opposite sides of the mandible. A limitation of this study design was the use of the first premolar site. This site proved to be a poor site for implant placement due to encroachment of the large root of the adjacent cuspid tooth.

The values recorded for BIC and BAFO for the SRF implants in this study are broadly consistent with those reported in

literature for a variety of SRF implants (Gotfredsen et al. 1992; Cochran et al. 1998). Comparable figures for BIC and BAFO for PRF implants are not available in literature, with the exception of the previously mentioned limited set of data provided by Buser et al. (2004). However, it is the relative performance of the two implant types within the study that is of concern. The clinical validity of such a comparison may be duly questioned on the grounds that the morphology of SRF and PRF implants is so different. Given the considerably greater surface area and inter-plateau area of a PRF implant to a similar length SRF implant, it may be questioned whether an equivalent %BIC or %BAFO is clinically necessary. In order to answer these questions, it is worth considering the definition of osseointegration as 'a direct structural and functional connection between ordered living bone and the surface of a load carrying implant' (Brånemark 1985). While BIC and BAFO are established histologic measures of the structural connection between implant and bone and interthread bone density, they do not provide a direct measure of the functionality of that connection. In isolation, they are not comprehensive measures of osseointegration. The quantification of the functionality of the connection between implant and bone is a more complicated and situation-dependent calculation, requiring other scientific tests such as mechanical testing and finite elements analysis. Furthermore, as woven bone has inferior load-bearing properties to ordered lamellar bone (Roberts et al. 1987), a calculation of the proportion of woven bone to lamellar bone in the interthread/plateau area might be appropriate as a further histomorphometric measure in this study.

This study showed that, even though higher values were recorded for measurements of BIC and BAFO for the SRF implants at all four time-points, the difference between these measurements for SRF and PRF implants was not significant. Given that PRF implants initially demonstrate a less intimate relationship with the osteotomy than SRF implants, this represents the strong performance on the part of the PRF implants in achieving effective parity for these parameters. As there was no statistically significant difference in the BIC and BAFO trends for both implant types

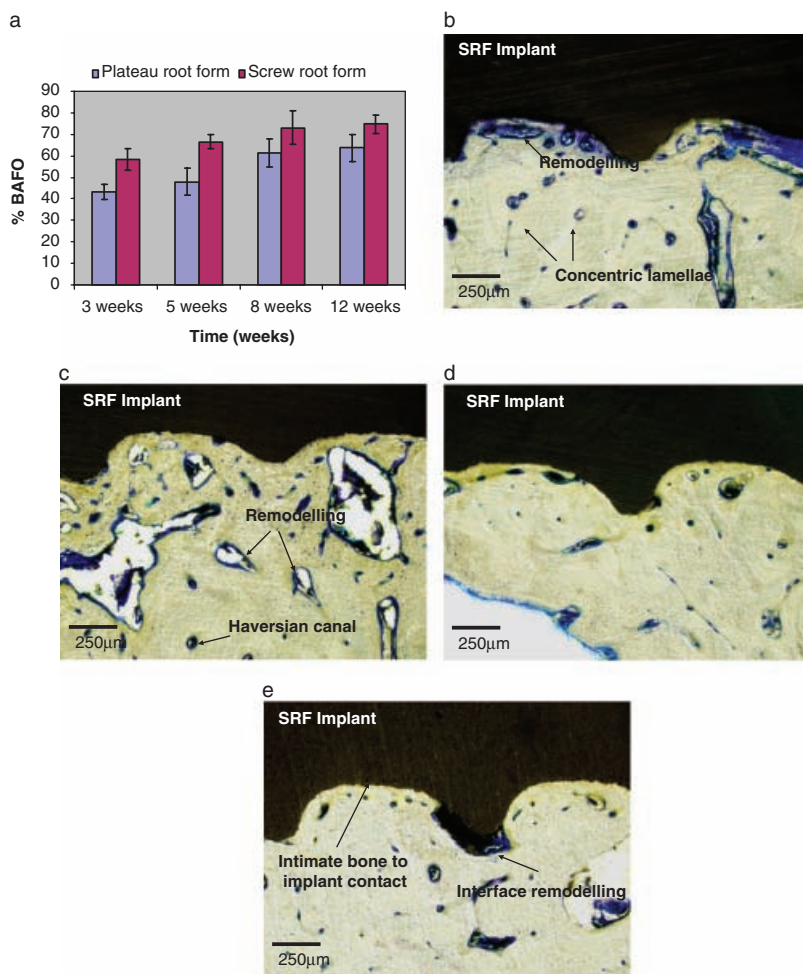


Fig. 10. (a) Graphic representation of mean %BAFO (percentage bone area fraction occupancy) and SE (error bars) for each time-point for plateau root form (PRF) and screw root form (SRF) implants. (b) Photomicrograph of ground section of SRF implant 3 weeks after placement ($\times 100$). (c) Photomicrograph of ground section of SRF implant 5 weeks after placement ($\times 100$). (d) Photomicrograph of ground section of SRF implant 8 weeks after placement ($\times 100$). (e) Photomicrograph of ground section of SRF implant 12 weeks after placement ($\times 100$).

between weeks 3 and 12 (the measurements increased in parallel), it can be speculated that there was more rapid bone

formation around the PRF implants between insertion and the 3-week time-point. In the absence of BIC and BAFO

measurements immediately after insertion, this cannot be scientifically verified. This may be considered a limitation of this study.

The results of this histomorphometric study of the bone healing process around PRF and SRF dental implants will contribute to the very limited body of scientific evidence available to date on this topic. The histomorphometric calculations, BIC and BAFO, provide a record of the structural connection between implant and bone at a light microscopic level. While this may be accepted as evidence of the rapid stabilisation of PRF implants, it must be recognised that, by definition, osseointegration requires both a structural and a functional connection between implant and ordered living bone (Brånemark 1985). In an age where the traditional 12-week healing period between the placement and functional loading of SRF implants is steadily decreasing, the poor load-bearing capacity of immature woven bone must raise questions as to the relative performance of PRF implants under such conditions. Further research will be necessary to investigate the relative functionality of the bone to implant connection for PRF and SRF implants in the traditional 12-week healing period post implant placement. This might involve a similar study design with mechanical testing of unloaded PRF and SRF dental implants.

Acknowledgements: The authors would like to thank Dr Vincent J. Morgan and Bicon[®] (Boston, USA) Implant Company for their support.

References

- Adell, R., Lekholm, U., Rockler, B. & Brånemark, P.I. (1981) A 15 year study of osseointegrated implants in the treatment of the edentulous jaw. *International Journal of Oral Surgery* **10**: 387–416.
- Albrektsson, T., Brånemark, P.I., Hansson, H.A. & Lindstrom, J. (1981) Osseointegrated titanium implants. Requirements for ensuring a long-lasting direct bone-to-implant anchorage in man. *Acta Orthopædica Scandinavica* **52**: 155–170.
- Albrektsson, T., Eriksson, A.R., Friberg, B., Lekholm, U., Lindahl, L., Nevins, M., Oikarinen, V., Roos, J., Sennerby, L. & Astrand, P. (1993) Histologic investigations on 33 retrieved Nobelpharma implants. *Clinical Materials* **12**: 1–9.
- Albrektsson, T. & Sennerby, L. (1991) State of the art in oral implants. *Journal of Clinical Periodontology* **18**: 474–481.
- Albrektsson, T., Zarb, G., Worthington, P. & Eriksson, R.A. (1986) The long-term efficacy of currently used dental implants: a review and proposed criteria of success. *International Journal of Oral & Maxillofacial Implants* **1**: 11–25.
- Berglund, T., Abrahamsson, I., Lang, K. & Lindhe, J. (2003) De novo alveolar bone formation adjacent to endosseous implants. *Clinical Oral Implants Research* **14**: 251–262.
- Brånemark, P.I. (1985) Introduction to osseointegration. In: Brånemark, P.I., Zarb, G. & Albrektsson, T., eds. *Tissue-Integrated Prosthesis. Osseointegration in Clinical Dentistry*, 11–76. Chicago, IL: Quintessence Publishing Co.
- Brånemark, P.I., Breine, U., Adell, R., Hansson, B.O., Lindstrom, J. & Ohlsson, A. (1969) Intraosseous anchorage of dental prostheses. I. Experimental studies. *Scandinavian Journal of Plastic and Reconstructive Surgery* **3**: 81–100.
- Buser, D., Brogini, N., Wieland, M., Schenk, R.K., Denzer, A.J., Cochran, D.L., Hoffman, B., Lussi, A. & Steinemann, S.G. (2004) Enhanced bone apposition to a chemically modified SLA titanium surface. *Journal of Dental Research* **83**: 529–553.
- Chess, J.T. (1990) Technique for placement of root form implants of the finned or serrated type. *Journal of the American Dental Association* **121**: 414–417.

- Cochran, D.L., Schenk, R.K., Lussi, A., Higginbottom, F.L. & Buser, D. (1998) Bone response to unloaded and loaded titanium implants with a sandblasted and acid-etched surface: a histometric study in the canine mandible. *Journal of Biomedical Material Research* **40**: 1-11.
- Coelho, P.G. & Suzuki, M. (2005) Evaluation of an IBAD thin-film process as an alternative method for surface incorporation of bioceramics on dental implants. A study in dogs. *Journal of Applied Oral Science* **13**: 87-92.
- Davies, J.E. (2005) Understanding peri-implant endosseous healing. *Journal of Dental Education* **67**: 932-949.
- Donath, K. & Breuner, G. (1982) A method for the study of undecalcified bones and teeth with attached soft tissues: the Sage-Schliff (sawing and grinding) technique. *Journal of Oral Pathology* **11**: 318-326.
- Driskell, T.D., O'Hara, M.J. & Greene, G.W. (1971) Surgical tooth implants, combat and field. Report No. 1, contract no. DADA17-69-C-9118, supported by the US Army Medical Research and Development Command.
- Fiorellini, J., Martuscelli, G. & Weber, H.P. (1998) Longitudinal studies of implant systems. *Periodontology 2000* **17**: 125-131.
- Gotfredsen, K., Nimb, L., Hjørting-Hansen, E., Jensen, J.S. & Holmén, A. (1992) Histomorphometric and removal torque analysis for TiO₂-blasted titanium implants. An experimental study on dogs. *Clinical Oral Implants Research* **3**: 77-84.
- Lemons, J.E. (2000) Structure of bone adjacent to different dental implants. In: Davies, JE, ed. *Bone Engineering*, 313-321. Toronto: Em squared Inc.
- Lemons, J.E. (2002) Biocompatibility of implant materials. Proceedings of the 3rd Annual Indiana Conference, Indiana School of Dentistry, Medical Education Resource Program, Indianapolis, IN, 79-89.
- Lemons, J.E. (2004) Biomaterials, biomechanics, tissue healing and immediate function dental implants. *Journal of Oral Implantology* **30**: 318-324.
- Roberts, W.E. (1988) Bone tissue interface. *Journal of Dental Education* **52**: 804-809.
- Roberts, W.E., Turley, P.K., Brezniak, N. & Fielder, P.J. (1987) Bone physiology and metabolism. *Journal of California Dental Association* **15**: 54-61.
- Rohrer, M.D. & Schubert, C.C. (1992) The cutting-grinding technique for histologic preparation of undecalcified bone and bone-anchored implants. Improvements in instrumentation and procedures. *Oral Surgery Oral Medicine Oral Pathology* **74**: 73-78.
- Sennerby, L. (2001) Implant integration and stability. In: Palacci, P & Ericsson, I, eds. *Esthetic Implant Dentistry*, 15-31. Berlin: Quintessence Publishing Co. Inc.
- Smith, D.E. & Zarb, G.A. (1989) Criteria for success of osseointegrated endosseous implants. *Journal of Prosthetic Dentistry* **62**: 567-572.
- Suzuki, K., Aoki, K. & Ohya, K. (1997) Effects of surface roughness of titanium implants on bone remodelling of femur in rabbits. *Bone* **21**: 507-514.